

# Introduction to MicroPulse for Central Serous Chorioretinopathy

MicroPulse laser has become one of our hospital's standard treatments for CSCR.

BY PROF. DR. SASCHA FAUSER, MD



I would like to introduce you to the principle of MicroPulse laser therapy.

To understand MicroPulse laser technology, we must first understand conventional photocoagulation.

With conventional photocoagulation, the laser transfers energy to the retina. The longer the laser beam is on, the more heat is generated. This heat may result in tissue damage by coagulating the proteins. It is similar to how an egg loses its transparency when heat is applied to it.

We do not yet know the exact mechanism of action of laser, but one hypothesis is that the damaged photoreceptors are replaced by glial cells, which have less oxygen consumption, less vascular endothelial growth factor (VEGF), less edema, and less neovascularization.

It turns out that you do not necessarily have to create a scar to have a laser effect. This is what MicroPulse technology uses. The laser energy is applied in short pulses to avoid heat buildup and results in no visible burns. Basically, the laser beam is cut into small pieces of on time and long pieces of off time. This allows the tissue to cool, which results in no scarring. This led to the duty cycle concept, which is the length of time the laser is on divided by the total time the laser is used. The use of the recommended settings results in no fibrous damage because the laser is on for 100  $\mu$ s and off for 1,900  $\mu$ s (5% duty cycle) (Figure 1).

One of the challenges with MicroPulse laser treatment is that you cannot visualize any laser effect during the treatment, which could give you the feeling that the treatment is not effective. Overall, the problem is overtreating, but undertreatment can also be an issue. To avoid undertreating, surgeons should apply dense treatment and focus the laser carefully. The yellow 577 nm wavelength has an advantage in these situations because, due to its absorption characteristics, it can be titrated. Basically, you apply the laser to the periphery of the edematous area (in a nonedematous area) on low power that is increased gradually until a just-visible effect appears. Once the thermal threshold is determined for a patient, you reduce the power to 50% of that threshold. This will ensure that no scarring occurs in the edematous area.

Lavinsky and colleagues participated in a study that compared traditional argon laser to MicroPulse and high-density MicroPulse.<sup>1</sup> The best gain in visual acuity was achieved in the high-density MicroPulse group. If the MicroPulse spots are administered as a nondense treatment, the patients were undertreated. For example, if you treat a given area with 25 spots that are one laser spot apart, the area receives less energy than if you apply the spots next to each other, which results in the delivery of three times more spots and thus three times more energy in that area (Figure 2).

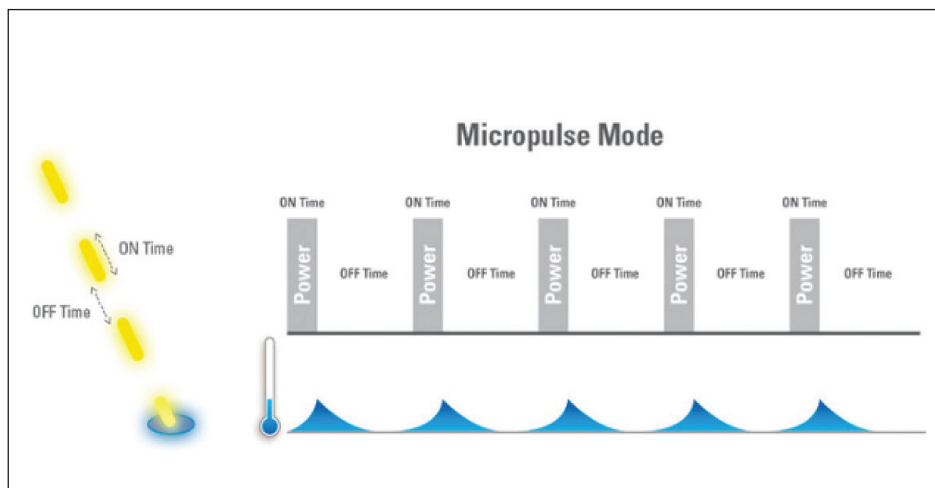


Figure 1. The use of the recommended settings results in no fibrous damage because the laser is on for 100  $\mu$ s and off for 1,900  $\mu$ s (5% duty cycle).

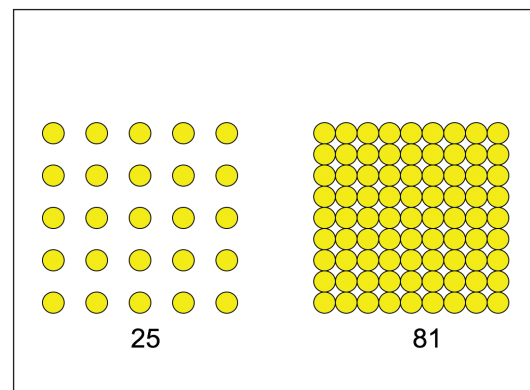
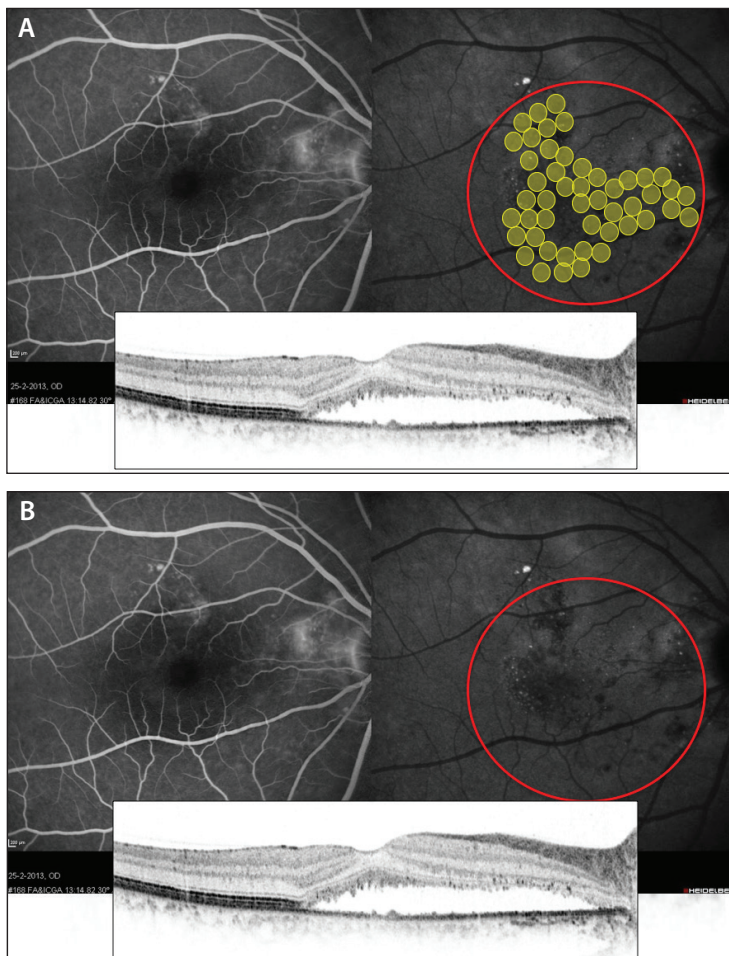


Figure 2. If you treat a given area with 25 spots that are one laser spot apart, the area receives less energy than if you apply the spots next to each other, which results in the delivery of three times more spots and thus three times more energy in that area.



**Figure 3.** Indocyanine green angiography-guided MicroPulse therapy (A) with the treatment settings presented in the Table (B).

TABLE. TREATMENT PARAMETERS/PROCESS SUMMARY	
Step 1	Step 2
<b>TITRATE POWER USING MONOSPOT &amp; MICROPULSE</b>	<b>MULTISPOT &amp; MICROPULSE TREATMENT SETTINGS</b>
Spot Size: 160 $\mu$ m	Resume function activation
Exposure Time: 0.2s (200ms)	Spot Size: 160 $\mu$ m
Duty Cycle: 5%	Spacing: 0
	Exposure Time: 0.2s (200ms)
Increase of the power level (step by step) until reaching a just visible endpoint (barely visible threshold burn).	Duty Cycle: 5%
	Use <b>50%</b> of the power level reached during the titrate step for treatment.
Treatment is based on OCT thickness map, treat the entire area of edema. NB: The most common cause of treatment failure is undertreatment.	

## Central Serous Chorioretinopathy

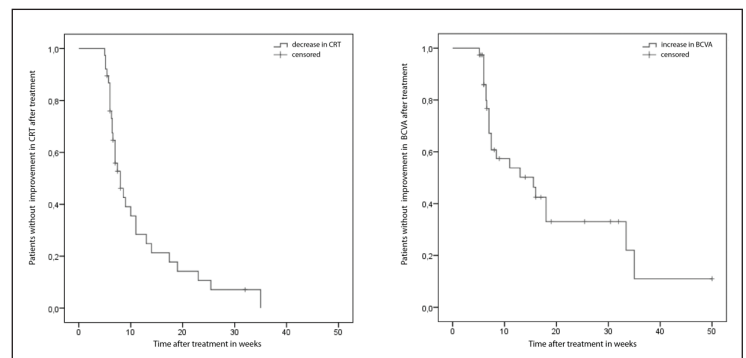
Central serous chorioretinopathy (CSCR) is one of the most common macular diseases. In the acute phase of CSCR, patients have fluid accumulation and focal pinpoint leakage. In the

“For the majority of patients with central serous chorioretinopathy, there are two viable treatment options: 577 nm MicroPulse laser and photodynamic therapy.”

chronic form of the disease, patients experience atrophy and irreversible vision loss. There is no clear definition to distinguish between the acute and chronic phases, but I usually treat patients if there is no resolution of fluid after 6 weeks.

What are the treatment options for the disease? One option is to wait because in a large number of patients the fluid spontaneously resolves. Physicians should also consider stopping steroids, if they are given. There is only one confirmed exogenous steroid therapy. Many other therapies have been tried, but some are not effective. In my experience, antagonists do not work and result in serious side effects such as increased potassium levels. Anti-VEGF agents work, but only if the patient has cystoid macular edema or age-related macular degeneration. For the majority of patients with CSCR, there are two viable treatment options: 577 nm MicroPulse laser and photodynamic therapy (PDT). With MicroPulse laser, I use the indocyanine green angiography-guided therapy (Figure 3) with the treatment settings presented in the Table. I wait 6 weeks for results, and I repeat the treatment if necessary. If the macula still has fluid, then I turn to PDT.

I participated in a study<sup>2</sup> with 38 patients who had a disease duration of 4 years. In these chronic cases, 75% of patients improved overall (24% had complete resolution of fluid and 50% showed improvement) after receiving MicroPulse laser. There was no change in 26% of the patients. I also saw that 61% of patients



**Figure 4.** In this study, patients’ central retinal thickness improvement was relatively prompt, but there was a time lag for the functional response or for the visual acuity recovery.

	Treatment response	Complete resolution of SRF	CRT ( $\mu$ m) baseline Mean $\pm$ SD	CRT ( $\mu$ m) after therapy Mean $\pm$ SD	P-Value ** Statistically significant difference before and after therapy
SML (n=42)	33 of 42 (79%)*	15 of 42 (36%)	445 $\pm$ 153	297 $\pm$ 95**	**p<0.001 Wilcoxon Signed-Ranks
PDT (n=58)	34 of 58 (59%)*	12 of 58 (21%)	398 $\pm$ 88	322 $\pm$ 93**	**p<0.001 Wilcoxon Signed-Ranks
P-Value	*p=0.036 Chi-squared test	p=0.095 Chi-squared test	p=0.242 Mann-Whitney-U-Test		
	Increase in BCVA of 1 or more lines	BCVA (LogMAR) baseline Mean $\pm$ SD	BCVA (LogMAR) after therapy	P-Value ** Statistically significant difference before and after therapy	Increase in BCVA (LogMAR) Mean $\pm$ SD
All patients (n=100)	50 of 100 (50%)	0.37 $\pm$ 0.24	0.31 $\pm$ 0.25**	**p=0.001 Wilcoxon Signed-Ranks	-0.059 $\pm$ 0.168
SML (n=42)	23 of 42 (55%)	0.39 $\pm$ 0.24	0.31 $\pm$ 0.27**	**p=0.003 Wilcoxon Signed-Ranks	-0.081 $\pm$ 0.167
PDT (n=58)	27 of 58 (47%)	0.35 $\pm$ 0.24	0.31 $\pm$ 0.24	p=0.077 Wilcoxon Signed-Ranks	-0.043 $\pm$ 0.169
P-Value	p=0.418 Chi-squared test	p=0.360 Mann-Whitney-U-Test			p=0.349 Mann-Whitney-U-Test

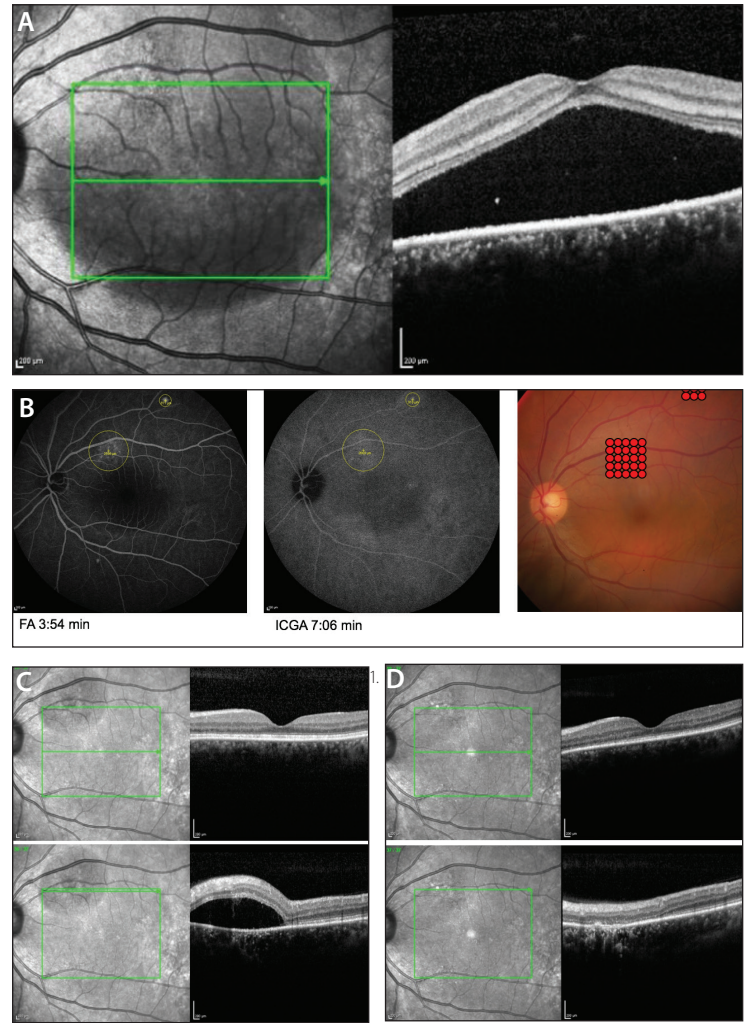
**Figure 5.** In the MicroPulse group, 80% of the patients improved (36% had complete resolution of fluid). MicroPulse was overall superior to PDT.

who had not responded to prior PDT treatment showed an improvement after MicroPulse laser. Visual acuity improved from 0.36 to 0.30, and there was a decrease in central retinal thickness. The central retinal thickness improvement was relatively prompt, but there was a time lag for the functional response or for the visual acuity recovery (Figure 4).

I participated in another study<sup>3</sup> with 100 patients who had a disease duration of 3.2 years that compared PDT and MicroPulse. The results were similar to the previous study. In the MicroPulse group, 80% of the patients improved (36% had complete resolution of fluid). The PDT group also showed improvement, but there was a statistically significant difference between the MicroPulse group and PDT group ( $P = .036$ ). MicroPulse was overall superior to PDT (Figure 5).

Here is a specific patient scenario. A 44-year-old man presented with a lot of leakage and visual acuity at 0.16. I treated him with the MicroPulse laser in November. When he returned in January for follow-up, the center of the macula was completely dry, there was some fluid in the periphery, and visual acuity had substantially improved. At this point, I did not do anything because there was essentially no fluid. When he returned in March, his visual acuity had further improved and the peripheral fluid was gone. It takes time before you see the treatment effects (Figure 6).

In summary, MicroPulse laser treatment is safe and efficacious for patients with CSCR, even for chronic cases or cases with prior treatment failure to PDT. It may be superior to PDT, but more studies are needed. At the moment, I am part of an ongoing randomized trial in Europe<sup>4</sup> that will compare MicroPulse versus PDT. Hopefully, that study will give us more information. ■



**Figure 6.** A 44-year-old man presented with a lot of leakage and visual acuity at 0.16 (A). He was treated with the MicroPulse laser in November (B). In January, the center of his macula was completely dry, there was some fluid in the periphery, and his visual acuity had substantially improved (C). In March, his visual acuity had further improved and the peripheral fluid was gone (D).

Lavinsky D, Cardillo JA, Melo LA et al. Randomized clinical trial evaluating mETDRS versus normal or high-density micropulse photocoagulation for diabetic macular edema. *Invest Ophthalmol Vis Sci.* 2011;52(7):4314-4323.  
 2. Scholz P, Ersoy L, Boon CJH, Fauser S. Subthreshold micropulse laser (577 nm) treatment in chronic central serous chorioretinopathy. *Ophthalmologica.* 2015;234(4):189-194.  
 3. Scolz P, Altay L, Fauser S. Comparison of subthreshold micropulse laser (577 nm) treatment and half-dose photodynamic therapy in patients with chronic central serous chorioretinopathy. *Eye (London).* 2016;30(10):1371-1377.  
 4. ClinicalTrials.gov. Prospective randomized controlled treatment trial for chronic central serous chorioretinopathy (PLACE). <https://clinicaltrials.gov/ct2/show/NCT01797861>. Updated April 1, 2016. Accessed December 15, 2016.

**Prof. Dr. Sascha Fauser, MD**

- department for vitreoretinal surgery, University Eye Hospital of Cologne, Germany
- [sascha.fauser@uk-koeln.de](mailto:sascha.fauser@uk-koeln.de)
- financial disclosure: consultant to Quantel Medical, employee of F. Hoffmann-La Roche